

Jacobs Journal of Clinical Case Reports

Case Series

Vaginal Giant Condyloma in Pregnancy Mimicking Carcinoma: Case Report

Soheila Aminimoghaddam^{*1}, Fatemeh Abbasi², Fatemeh Mahmoudzadeh³, Andisheh Maghsoudnia⁴, Fatemeh Ghaemmaghami⁵

¹Iran University of Medical sciences, Firoozgar hospital, Tehran, Iran.

²Fellowship of Gyneco-oncology, Tehran University of Medical sciences, Iran

³Mazandaran University of Medical Sciences, Sari, Iran

⁴Tarbiat Modares University, Tehran, Iran

⁵Department of Gynecology Oncology, Vali asr Hospital, Tehran University of Medical Sciences, Tehran, Iran

**Corresponding author:* Dr. Soheila Aminimoghaddam, fellowship of Gynecology Oncology, Iran university of Medical Sciences, Firoozgar hospital, Tehran, Iran, Email: dr_aminimoghaddam@yahoo.com

Received: 08-24-2015

Accepted: 10-20-2015

Published: 12-09-2015

Copyright: © 2015 Aminimoghaddam

Abstract

Background

Today, at least 1 million new cases of genital warts are diagnosed every year and, it seems that human papillomavirus and its related conditions such as genital warts show an increasing trend.

Case presentation

We report a 24 years old pregnant woman in her 21st weeks who was referred due to a large cauliflower mass protruding from vagina. She underwent surgical excision.

The post operative period was uneventful and she had a term delivery with a normal appearance new infant.

Discussion

Sensitive detection tests for HPV DNA indicate that as many as 30% of sexually active adults may be infected; a similar rate is seen in pregnancy. Genital wart is a clinical manifestation of low risk HPV types 6 and 11, it often increases in size and number during pregnancy. Therapeutic management in this situation that may affect fetus, can pose some problems. Our case was a pregnant woman with giant condyloma likely to verrucose carcinoma which malignancy excluded and managed with surgery.

Occasionally, condyloma in the pregnancy after the first trimester which becomes large and macerated would require surgical excision.

Keywords: Genital Warts; Pregnancy; Carcinoma; Human Papillomavirus 6

Introduction

Genital warts is one of the most prevalent sexually transmitted disease in the world. Both, the incidence and the prevalence of genital HPV infection are increasing [1].

The viral nature of genital was first known in 1907 when ci-uffo induced warts after auto inoculation of free-cell wart extracts. The DNA of the first genital wart was characterized in 1980. now, at least 100 HPV types have been identified; about 40 type of them affect the male and female anogenital tract [1].

Estimates indicate, about 1 % of the sexually active populations have clinically apparent genital warts [2].

In the mid-1970 s, Zur Hansen proposed that HPV has probably an important role in the etiology of genital tract neoplasia [1].

Type 6&11 of HPV can cause 90% of all genital warts. Most of people who get these two strains never develop any symptoms and visible warts. HPV may also cause cervicitis. Types 16&18 can cause cancer [3].

Approximately 40 different types of HPV can infect the anogenital tract.

An increased prevalence of anogenital HPV infections during pregnancy is reported by several investigators. The risk of condyloma acuminatum in pregnancy is 2-fold [3].

Case Presentation

We are reporting a 24 years pregnant woman who was referred to Vali Asr Gynecology Oncology clinic due to a huge cauliflower mass that was protruding in vagina. She was G3p1 Ab1, in her 21st weeks of gestations. two months ago She has had multiple small warty lesions on her labia major and minor that had been treated by cryotherapy.

After that, her lesions repeated in larger shape.

She complained of burning sensation and vaginal discharge and also dysuria.

Her ultrasonic examination revealed a 21 -week- fetus without any abnormality. All her serologic tests including HBSAg-HBSAb-HCVAb-VDRL-HIV were negative. in physical examination, was found a 10 * 7 cm cauliflower like tumor mass that was protruding in vagina [figure 1] and also some scattered-multiple small warts on mons pubis, Labia major & minor ,sub urethra, perineum and peri anal regions. HPV DNA typing by PCR showed types 6&11. Patient Pap smear was normal, she underwent a wide local excision that send for pathology. [Fig-

ure 2] The mass originated from the low posterior aspect of vagina. All of the other lesions were cauterized. She was under observation until small lesions appeared on perineum and inner aspect of labia minor that responded to TCA 90%.

Her Colposcopic examination did not clear any problems.

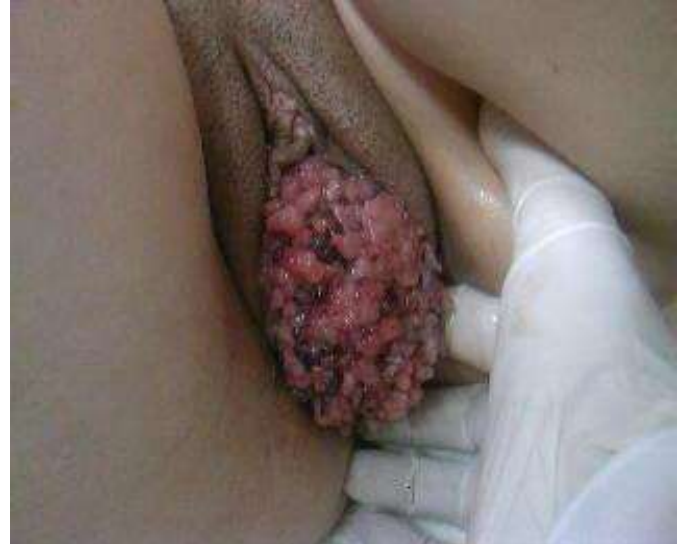

Figure 1. Large mass.

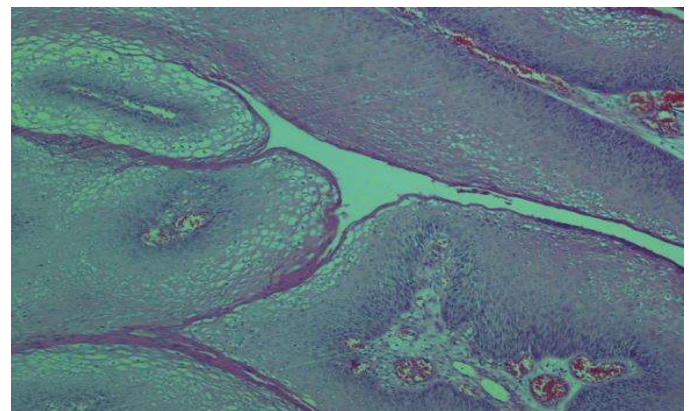
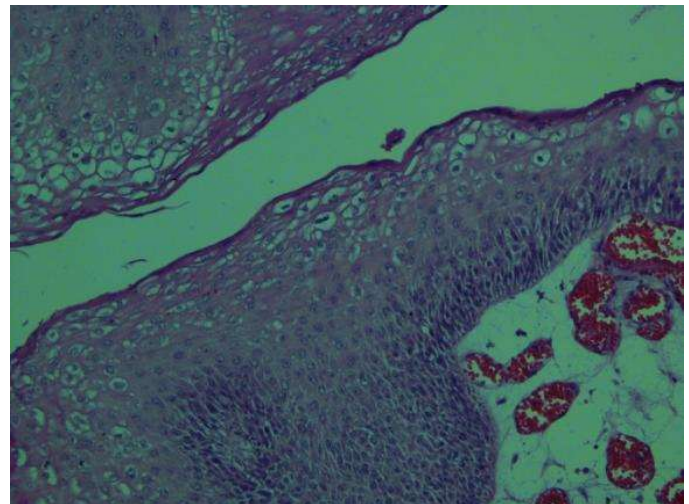


Figure 2. Pathology;Typic Koilocyte is seen.

Discussion

Globally, HPV is the most common sexually transmitted infection. Genital warts are spread by sexual contact. Approximately two thirds of sexual contact with an infected partner show genital wart. The incubation period is 3 months. Most of these infections are transient.

The common symptoms of genital warts are:

1. Red, pink or gray-colored cauliflower-shaped lesions in genital and area that looks raised or flat .These bumps may grow in large clusters and expand into huge masses very rapidly.
2. Moisture and dampness increase in the infected area.
3. An increase in vaginal fluid excretion.
4. Pain and bleeding during and after sexual intercourse. This is usually more painful for women since their genital warts can manifest inside cervix and vagina.
5. Discomfort and itching in the affected areas. This is common confused for a simple rash. Warts are usually painless in nature in mild case. They may inflict extreme pain in severe cases.

HPV infection of the vulva can result vulvar intraepithelial Neoplasial or squamous cell carcinoma of the vulva. HPV can cause cervical and vaginal dysplasia and carcinoma. Using oral contraceptives increase genital warts incidence because of unprotected sexual intercourse and impaired metabolism of vitamins and folic acid. Excessive smoking may also increase genital warts [4]. Furthermore having a comprised immune system due to hormonal changes in pregnancy raise genital wart risk. Thus, genital warts may become larger during pregnancy; clearance of HPV appearing is slowed during the first and second trimesters of pregnancy [5]. The unborn infants of a infected mother with genital wart during postpartum period may acquire laryngeal papillomatosis, which is a life-threatening condition. Approximately 5% rate of all births that are at risk of neonatal HPV exposure is extremely low (2000 cases per year US). This would imply that mother to infant transmission is low and so is not recommending cesarean delivery for prevention of laryngeal papillomatosis. If the mother has huge condyloma that interferes labor and delivery or if it is risk of excessive bleeding during birth, a cesarean delivery may be needed [6]. People who are diagnosed with condylomata acuminata are at increased risk for other sexually transmitted disease. Consider testing for chlamydia, gonorrhoea, syphilis, hepatitis B, hepatitis c, herpes and HIV diagnosis depends on the clinical situation. If the pap smear test of the cervix has not performed in the last 12 months, it is necessary to be done for

these patients.

There is no single definitive treatment for HPV infection in pregnancy. Treatment is depended on the size, location and number of identified lesions and needs removal or ablation of all visible warts because of these lesions tend to proliferate recurrences that usually occur during the first 3 months after treatment, and a follow-up evaluation should be offered. In pregnant women topical application of 80% to 90% trichloro acetic acid (TCA) can be used ,For small lesions cryotherapy with liquid nitrogen has also been successful and is a reasonable first-line treatment .usage in the vagina not recommended because of the risk of vaginal perforation and fistula formation [6] .

Laser therapy with carbondioxide is recommended for those patients with large or multiple lesions or with lesions refractory to TCA or cryotherapy [6]. Surgical removal is recommended in pregnancy specially for giant vaginal warts.

Imiquimod 5% cream ,podophilin or intralesion interferon or antiviral drug is not recommended in pregnancy [6,7].

Conclusion

Condylomata acuminata is a morphologic manifestation of HPV infection in the lower genital tract. Histopathology and virology studies of vulvar lesions has demonstrated an association between HPV 6 and 11 with approximately 90% of exophytic vulvar condyloma as well as flat cervical condylomas and some low grade cervical neoplasia. Giant condyloma is seen in immunosuppress situation like as pregnancy. Surgical excision is a good treatment for giant vaginal condyloma.

Our case was a pregnant woman with giant condyloma like to verrucous carcinoma which malignancy excluded and managed with surgery.

The keys for fighting with genital warts are prevention, early detection and immediate treatment.

Acknowledgment

Special thanks to Vali Asr gynecology oncology clinic persons at Emam Khomeini complex hospital.

References

1. Muñoz N, Bosch FX, de Sanjosé S, Herrero R, Castellsagué X et al. Epidemiologic classification of human papillomavirus types associated with cervical cancer. *N Engl J Med.* 2003, 348: 518-527.

2. Koutsky L. Epidemiology of genital human papilloma virus infection . AM J Med. 1997 , 102(A): 3-8.
3. Gross G, Ikenberg H, Gissmann L, Hagedorn M et al. Papillomavirus infection of the anogenital region. Correlation between histology, clinical picture and virus type. J Invest Dermatol. 1985, 85(2):147-152.
4. Kjellberg L, Hallmans G, Ahren AM, Johansson R, Bergman F et al. Smoking, diet, pregnancy,oral contraceptive use as risk factors for cervical intraepithelial neoplasia in relation to human papillomavirus infection Br J Cancer. 2002, 82(7): 1332-1338.
5. Nobbenhuis MA, Heimerhorst TJ, van den Brule AJ, Rozendaal L, Bezemer PD et al. High-risk humanpapilloma virus clearance in pregnant women trends for lower clearance during pregnancy with a catch-up post partum. Br J Cancer. 2002,87:75-80.
6. Workowski KA, Bolan GA. Sexually transmitted diseases treatment guidelines2015. Atlanta: centers for disease control and prevention. MMWR Recomm Rep. 2015, 64 (RR-03): 1-137.
7. Snoeck R, Bossens M, Parent D, Delaere B, Degreef H et al. Phase II double-blind,placebo-controlled study of the safety and efficacy of cidofovir topical gel for treatment of patients with human papilloma virus infection .Clin infect Dis. 2001, 33(5): 597-602.